CORTICAL IMPLANTS

For Immediate Loading in:

- Post Extraction Sites
- Narrow Ridges
- Socket Shield Technique



NORIS Medical
ENGINEERED FOR HEALTH

Table of Contents

Cortical implant enables bi-cortical anchorage thus increasing the primary stability which is required for immediate loading.

- Cortical Implants are aggressively threaded implants that provide primary stability and bi-cortical anchoring. These implants allow for immediate loading due to their primary high stability in the Jawbone.
- Cortical Implants are intended for cases with narrow ridges or sockets with less than 4 walls. Additional indication is "Socket shield technique".
- Cortical Implants are designed to have a smooth surface at their “Neck” followed by an non-threaded, RBM treated surface. The smooth neck surface reduces the adherence of Perio-Pathogens thus reducing the development of inflammatory process around the neck area (i.e mucositis and peri-implantitis) and the RBM treated surface increases the BIC.

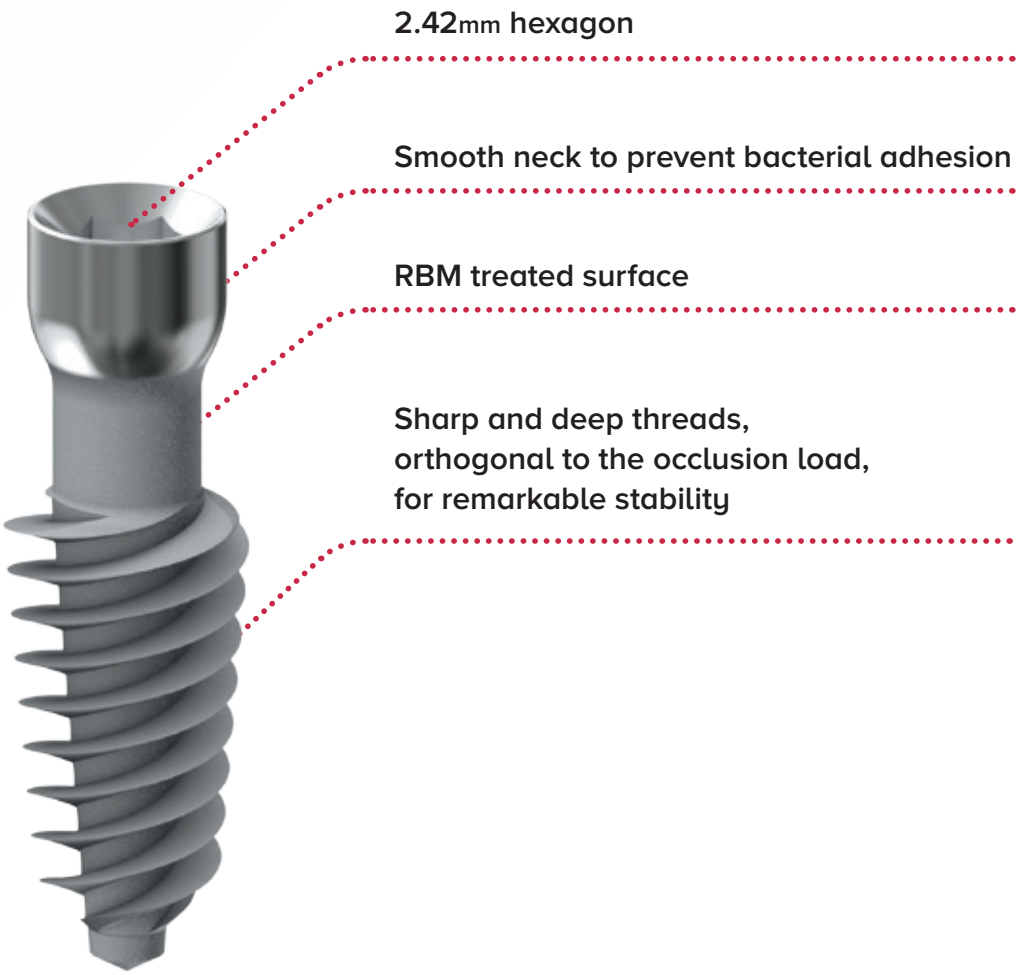

Implants	Ø D (mm)	L (mm)	L1 (mm)	L2 (mm)	Item
	4.0	10	4.5	5.5	NM-M4010
		11.5	4.7	6.8	NM-M4011
		13	5	8	NM-M4013
		16	6	10	NM-M4016
	5.0	8	4.1	3.9	NM-M5008
		10	4.5	5.5	NM-M5010
		11.5	4.7	6.8	NM-M5011
		13	5	8	NM-M5013
		16	6	10	NM-M5016
	6.0	8	4.1	3.9	NM-M6008
		10	4.5	5.5	NM-M6010
		11.5	4.7	6.8	NM-M6011
		13	5	8	NM-M6013

Cover Screw Included with all implants  NM-S5023

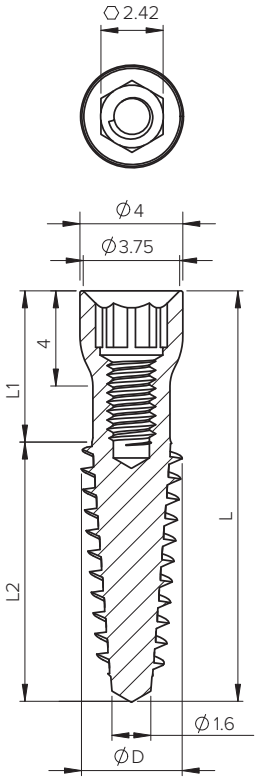

Drilling Speed (RPM)	1200-1500	900-1200	500-700	200-500	400-700	200-500
Drill Diameter	md	ø2.0	ø2.8	ø3.2	ø3.2	ø3.65

Drill Sequence*
Bone type D1, D2

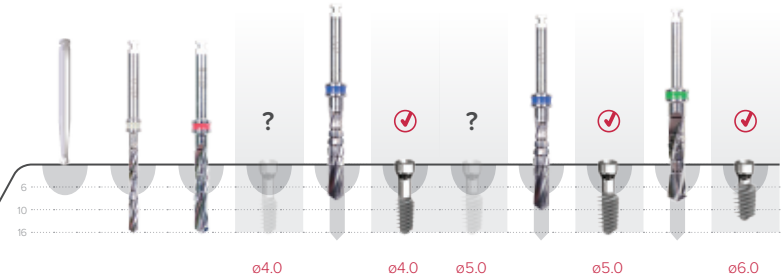

? *Torque Too high* ⟶ *Further Drilling Sequence* ✓ *Insert Implant*

Drilling Speed (RPM)	1200-1500	900-1200	500-700
Drill Diameter	md	ø2.0	ø2.8

Drill Sequence*
Bone type D1, D2

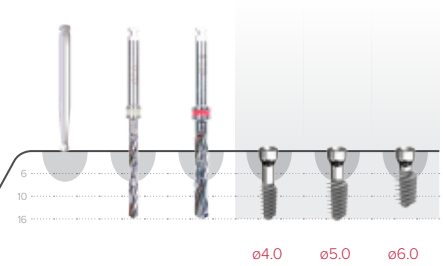

* The proposed procedure is only a recommendation and should not replace the doctor's judgment.
The implants may be placed in immediate function when good primary stability (above 35 Ncm) has been achieved and with appropriate occlusal loading.
* **Implant Carrier removal** After the osteotomy preparation, the implant should be inserted with the aid of the implant carrier.
The implant should be initially stabilized by a few threads and then the carrier should be removed. Farther insertion of the implant will be done with appropriate tool.
* **Implant hexagon** During implant insertion, the hexagon of the implant, should be located with a straight part of the hexagon toward the angulation needed, in order to provide adequate rehabilitation.

Dental Implantation Treatment plan – Planning ahead

With the courtesy of Dr. Balan Igal D.M.D.

Dental Implantation has been in use for about 50 years. During this period of time, many technological and biological developments that contributed significantly to the high success rate of implantations, have taken place.

Measureable quantitative and qualitative criteria for determining the success rate of dental implants have been set by various researchers such as Alberktson and others.

The use of dental implants as part of routine dental care is growing. However, with the number of implants installed, we observe a marked increase in failure rates as well as in the incidence of pathological processes such as mucositis and perioimplantitis.

Long-term follow-ups and vast accumulated knowledge reveal a less optimistic picture of dental implantation, and the illusion that dental implants can serve as long term substitutes for natural teeth is beginning to dissipate.

Nowadays we see more and more implants losing their bony support, and aside of functional failures there is also deterioration in the uncompromised aesthetic aspect.

Therefore, more and more often clinicians are faced with the need for an upfront treatment planning of complicated cases which involve the removal of previously installed failed implants.

Having to deal with failures raises questions about the key rules in planning of implantation procedures, for example:

As it is well known, 16 mm or even 13 mm Long implants, show stability even after losing half of their support. However, once their support has been compromised, a non-reversible damage is being caused which makes their replacement,

in case of failure, much more difficult. Based on this premise, the question that comes forth is whether to choose long implants or short implants to start with.

When we offer a treatment plan to a patient who had previously installed implants that failed, we should take into consideration the etiological factors that led to this failure. It is also important to understand that the use of implants is not a lifetime solution, and therefore the planning has to take into consideration future needs of the patient.

The following case presents a 64 years old female patient

The clinical examination showed:

- Chronic generalized severe periodontitis;
- Peri-Implantitis and Mucositis around implant's in the lower jaw;
- Calculus and plaque accumulation;
- Implant's threads exposure;
- Bleeding on probing;
- Periodontal pockets and mobility;
- Secondary caries in some of the restorations;
- Periapical lesions around teeth 34-35;

Treatment plan:

- Clearance - Extractions of all teeth and implants (mandible and maxilla);
- Installation of 7 implants in maxilla, out of which:
  - 2 Tubero Pterygoid Palatine implants (TPP);
  - 1 Zygoma implant by extra maxillary approach;
  - 2 tilted implants (the right one being parallel to the sinus mesial wall);
  - 2 parallel implants at the anterior region;
- Lower jaw- 5 implants, out of which 4 in the intremental region. 4 of which are Cortical type implants;

Lower jaw:

1

Clinical image of the lower jaw prior to the extraction.
Calculus and Plaque accumulation, Implant Threads exposure, Peri-Implantitis and Mucositis are observed.

2

Old Implants post extraction.

3

Lower jaw after the extractions. Extensive bony defects at the extraction sites are observed.



4

A Cortical implant with aggressive threads, designed to provide excellent primary stability.

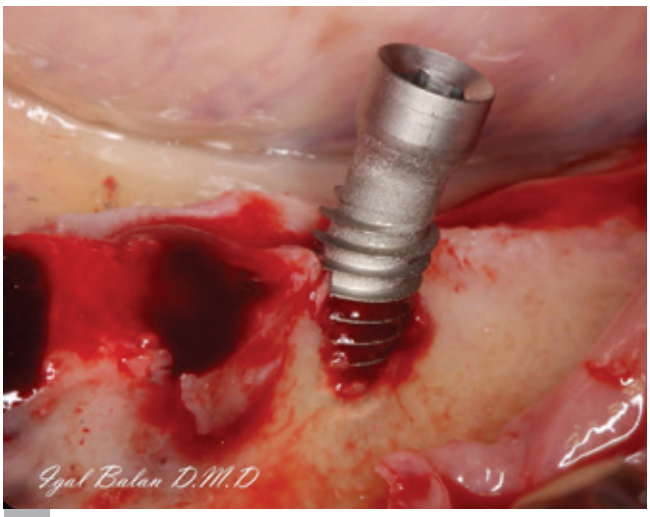

5

Cortical implant inserted at the extraction site.

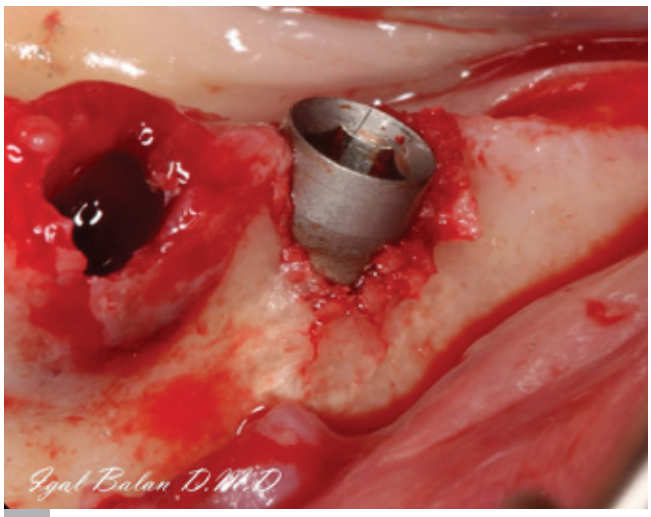

6

The neck of the implant remains exposed. The smooth neck minimizes the adherence of periopathogens.

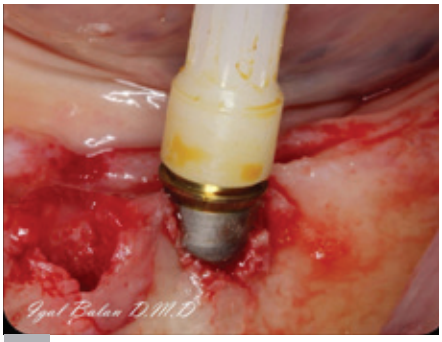

7

A Multi-Unit abutment is mounted on the implant.

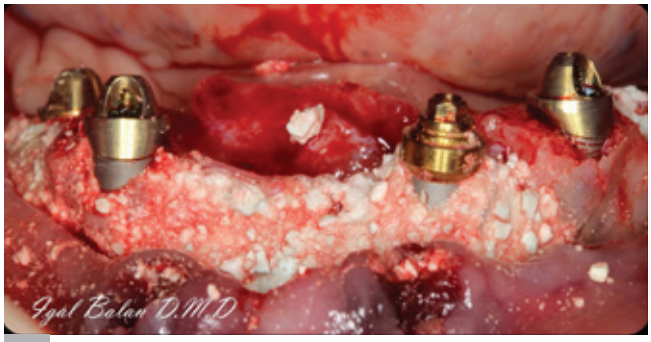

8

Bone augmentation using HA & Calcium sulfate bone graft

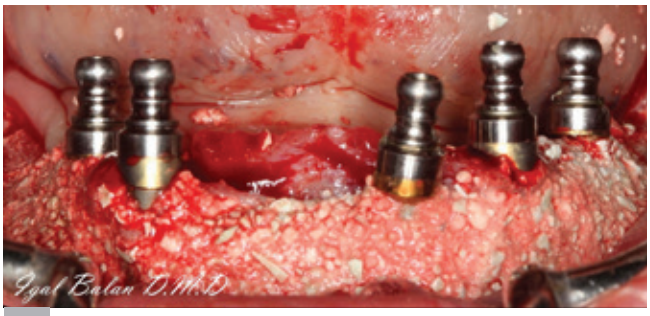

9

Snap-On Transfer bases are mounted on the Multi-Unit.

10

Suturing around the transfer bases

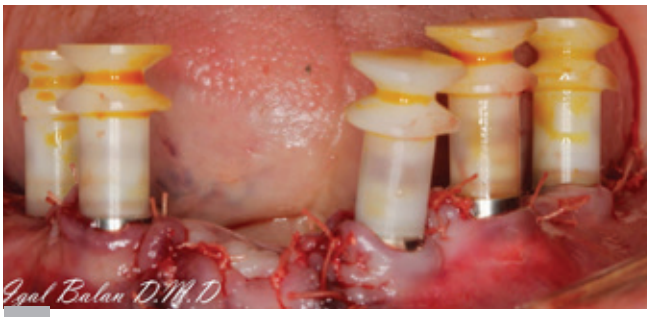

11

The female components of the transfers are being mounted on the male components.

12

Reinforced provisional lower acrylic bridge.

13

Occlusal view of the lower acrylic bridge.



14

Panoramic X-Ray (with the provisional bridge) at the end of the operation.

Immediate loading protocol of a cortical implant placed in a post extraction socket with an extensive bone loss

With the courtesy of Dr. Balan Igal D.M.D.

Primary stability (mechanical stability) of the dental implants is a key factor with high correlation to implant survival rate. Micro movements that exceed 200µm may result in implant failure. Insertion and loading of an implant placed in a fresh socket requires adequate primary stability. Due to its aggressive threaded design, the Cortical implant enables bi-cortical anchorage thus increasing the primary stability which is required for immediate loading.

The following case presents an implant placement in a post extraction site after enucleation of a specimen which was later diagnosed as a radicular cyst. The chronic inflammatory process caused severe bone loss.

61 years old female patient

Non-smoker. Declares to be of good health.

Chief complains:

- Unstable denture in the lower jaw;
- Impaired aesthetic;
- Teeth mobility;
- Bad breath odor;

Clinical examination:

- Lower jaw: Moderate alveolar bone loss and root remnants;
- Upper jaw: Chronic generalized severe periodontitis, severe bilateral alveolar bone loss of posterior maxilla and secondary caries. Additionally, extensive periapical lesions were detected (fig 1);

Treatment plan:

- Extraction of roots remnants;
- Cyst enucleation in the location of teeth 13 and 14 (the cyst was histologically diagnosed as “Radicular Cyst”);
- The cyst caused an extensive bone resorption with a wide destruction of the buccal plate (fig 2 and 3). It was decided to place a Cortical implant at the location of the enucleated cyst (fig 4 and 5);
- The implant is to be placed at a 30° angle, parallel to the mesial wall of the maxillary sinus. The angulation will be later corrected by a 30° Multi-Unit abutment (fig 6);
- The implants would be immediately loaded and rehabilitated by a screws retained acrylic bridge, reinforced by a 3 mm induction welded titanium (grade 5) bar;

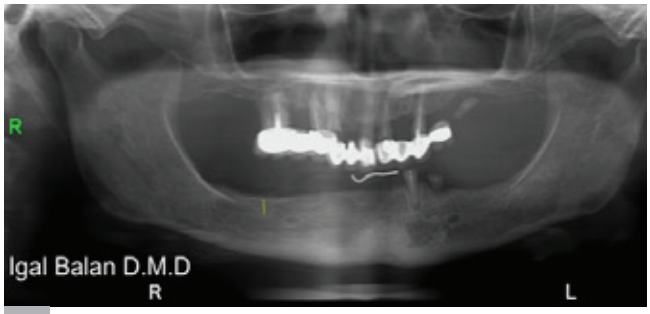

1

The panoramic X-ray illustrates chronic generalized severe periodontitis and severe bilateral alveolar bone loss.

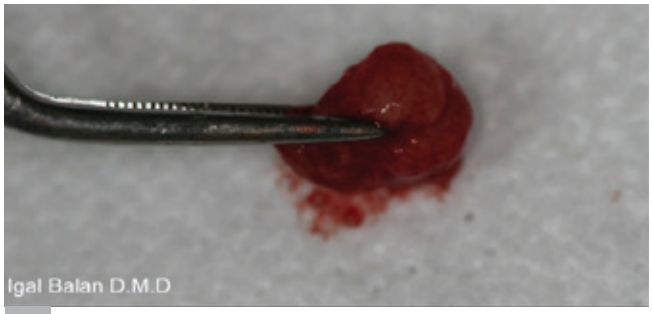

2

Radicular Cyst that was enucleated from the location of the teeth 13, 14.

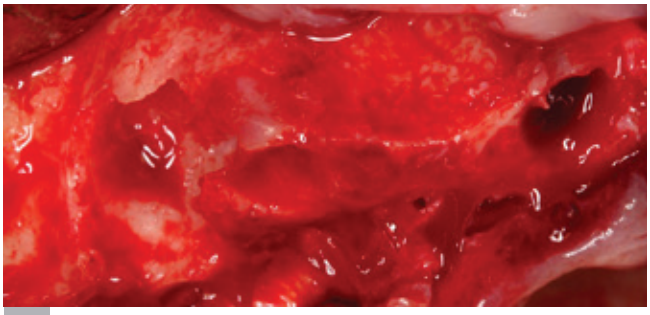

3

Enucleation site

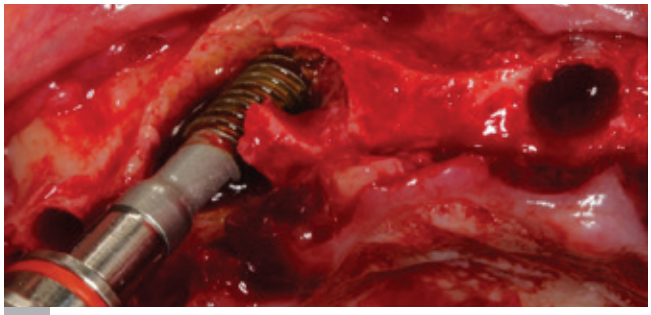

4

A Cortical implant (4x16) placed at the location of the major bone loss.

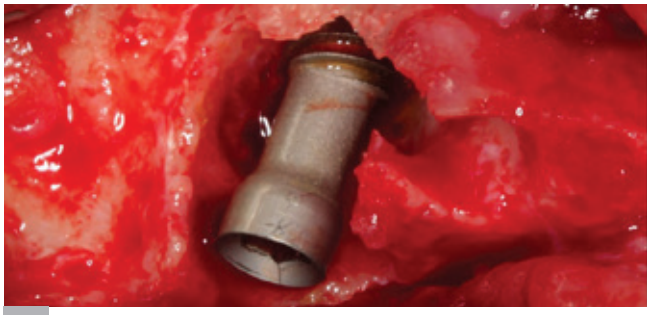

5

Despite the extensive bone loss, the recommended initial stability (over 45Ncm) for immediate loading was obtained.

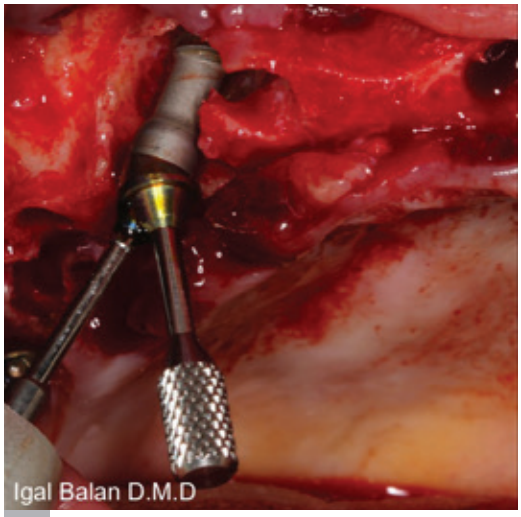

6

A Multi-Unit abutment is mounted on the implant in order to compensate for the angulation.

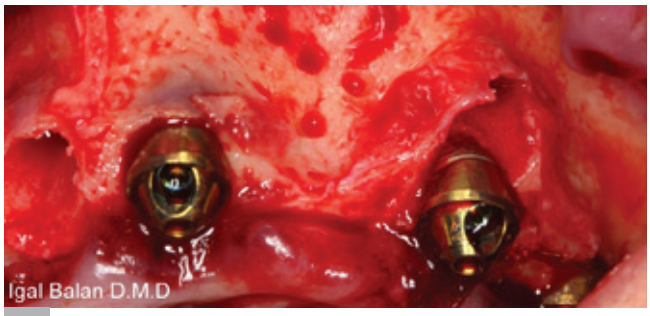

7

Decortication of the bone prior to bone grafting.

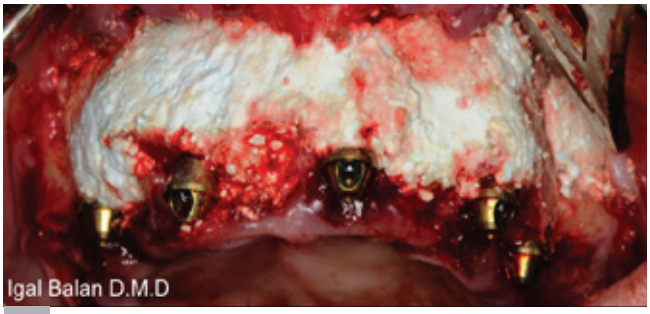

8

Bone augmentation using HA & Calcium sulfate bone graft.

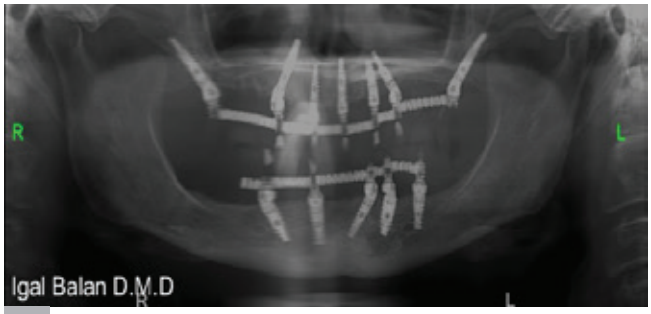

9

Post op. panoramic X-ray, taken at the day of the operation.

Protocol of an Immediate Loading Procedure in Severe Mandibular Atrophy

With the courtesy of Dr. Balan Igal D.M.D.

A 79 year old patient

Non-smoker.

Anamnesis:

- Controlled Hypertension;
- Hypothyroidism;
- Mastectomy (15 years prior to the date of examination);

Principal Patient's Complaints:

- Impaired aesthetic;
- Difficulty in chewing due to loss of posterior teeth;
- Bad breath odor;
- Teeth mobility;

Intraoral examination:

- Severe bilateral alveolar bone loss – posterior mandible. (Fig.1);
- Reduced posterior occlusal support;
- Chronic generalized severe periodontitis;

Treatment Plan:

- Mandibular clearance (Fig.2);
- Placement of four implants:
  Two Cortical implants at the extraction sites;
  Two tilted implants at the posterior area;

Cortical implants are aggressively threaded implants that provide primary stability and bi-cortical anchoring (Fig3). These implants allow immediate loading due to their primary high stability.
Cortical implants are provided with a smooth "Neck" surface (i.e. with no aggressive roughness).
The smooth neck surface reduces the adherence of perio-pathogens thus reducing the development of inflammatory process around the neck area (i.e. mucositis and peri-implantitis).
The tilted implants are to be installed as distally as possible in order to shorten any possible extension and its resulting cantilever effect.
These implants are also of the smooth neck surface type, for the same reasons as detailed above (Fig4);

- The implants would be immediately loaded and rehabilitated by a screws retained acrylic bridge, reinforced by a 3 mm induction welded titanium (grade 5) bar;
- The bridge to be is a screw retained type restoration, based on angle correcting multi unit abutments;

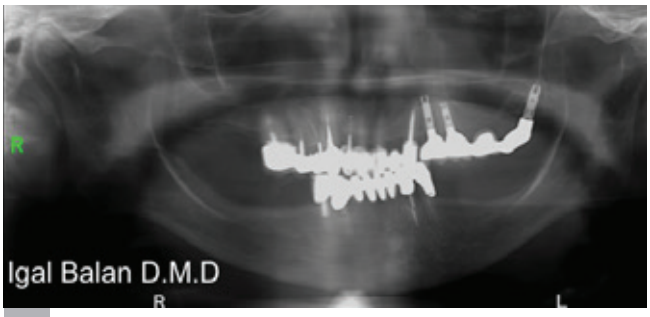

1

Panoramic X-Ray demonstrating extensive bone loss in the posterior mandible.

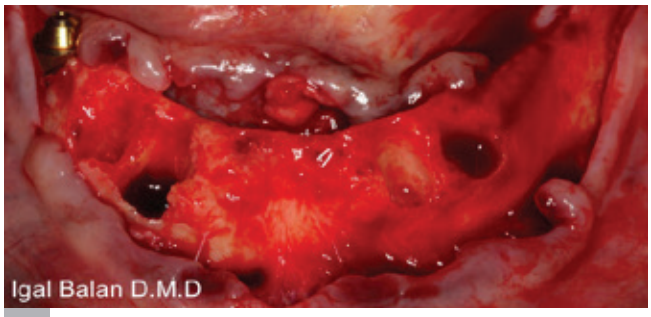

2

Post extraction site

3

Cortical implant (4X18 mm) with an aggressive thread for a better primary stability and with a smooth neck surface for reduction of bacterial adherence and inflammatory process development.

4

TUFF Implant (37.5X11.5 mm) with a smooth neck surface for reducing bacteria accumulation and infection.

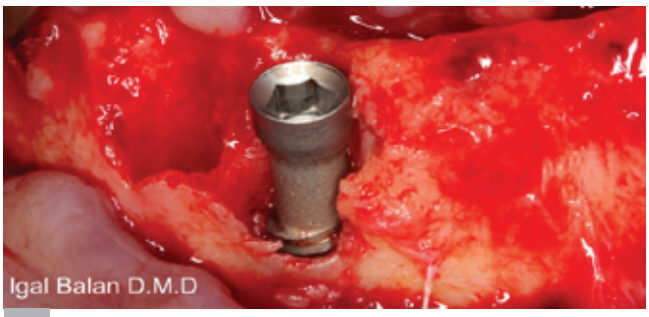

5

Cortical implant located in the extraction site of tooth 43. The Coronal area is left exposed due to bone loss.

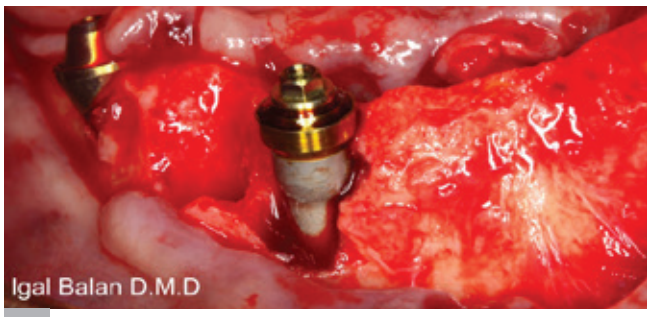

6

Straight Multi-Unit abutment mounted on the Cortical implant.

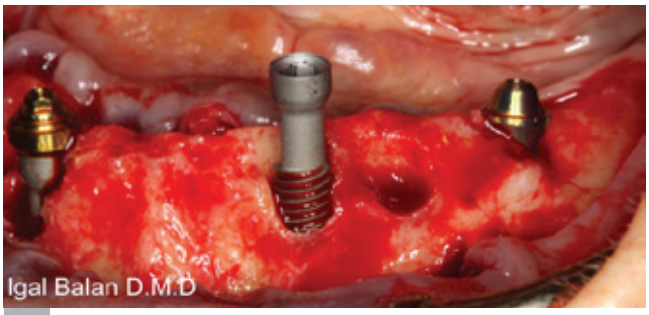

7

Cortical implant (4X20 mm) located in the extraction site of tooth 33.

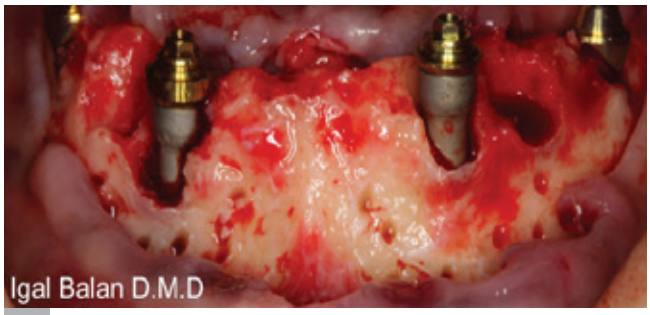

8

Four implants with Multi-Units showing the Decortication of the bone prior to bone grafting.

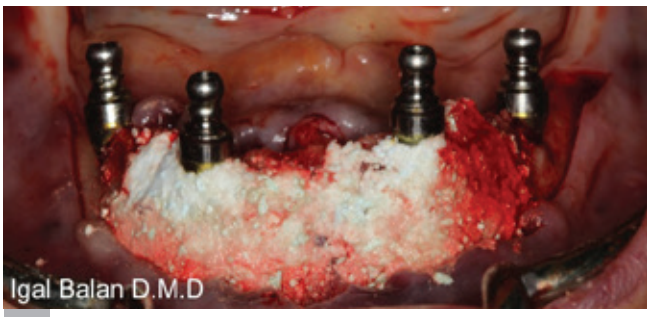

9

Bone augmentation using HA & Calcium sulfate bone graft.

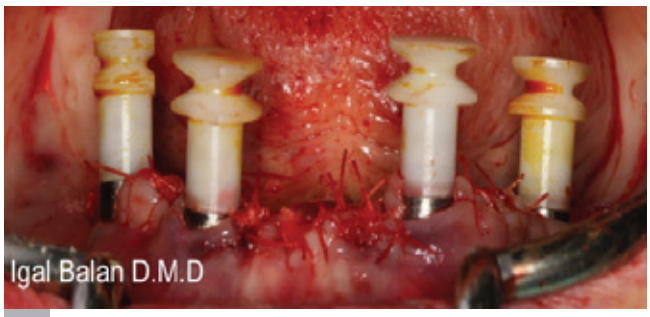

10

Snap-on Transfer for an easy impression taking using closed tray technique.

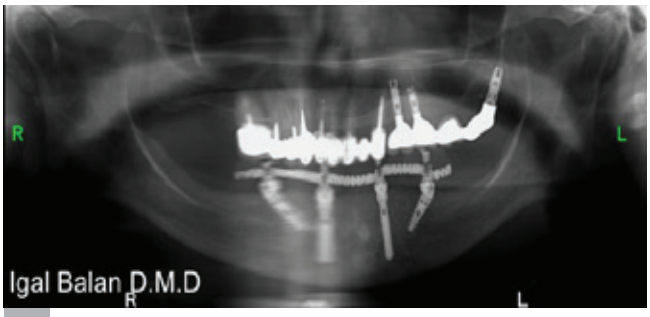

11

Post op. panoramic X-ray, taken at the day of the operation.

Post Extraction Site | Clinical Case No. 4

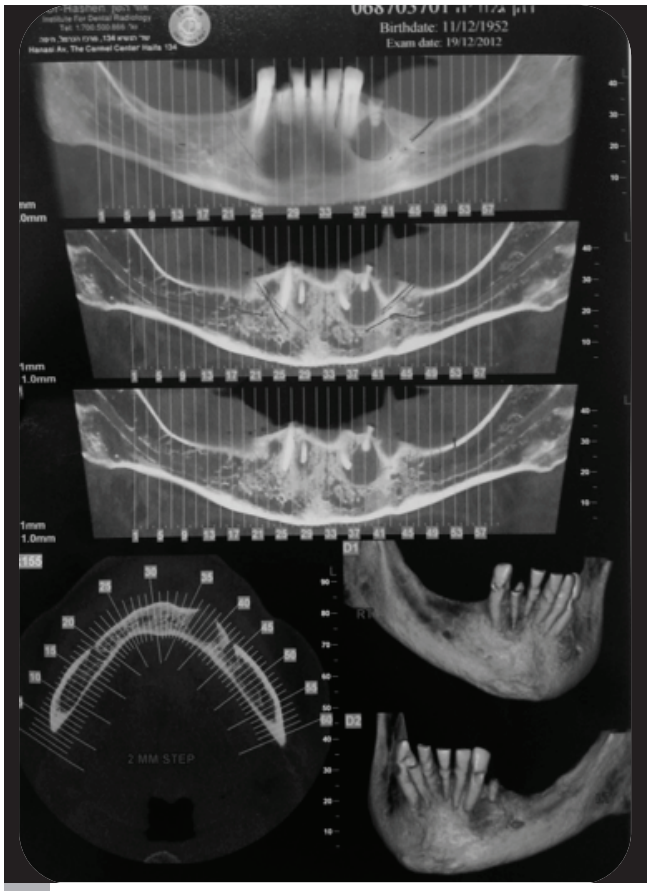

1

CT illustrates Periapical Radiolucencies.

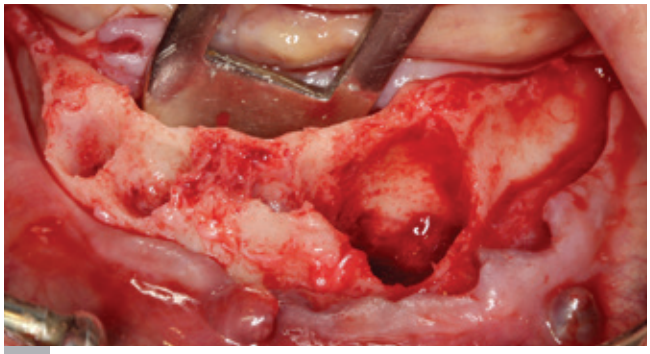

2

Post Extraction Site showing major bone loss.

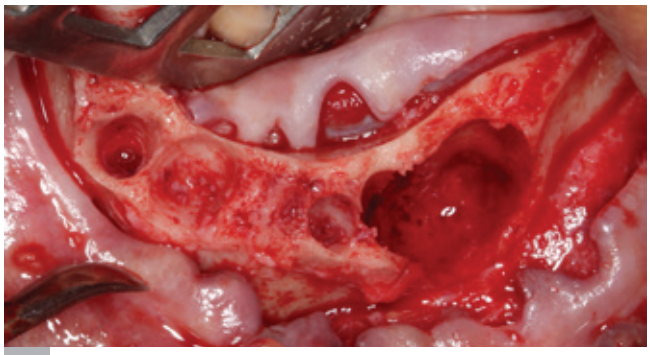

3

Post Extraction Site showing major bone loss.

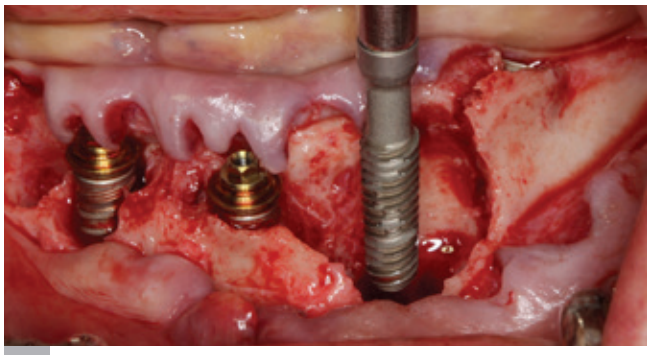

4

Insertion of a Cortical implant.

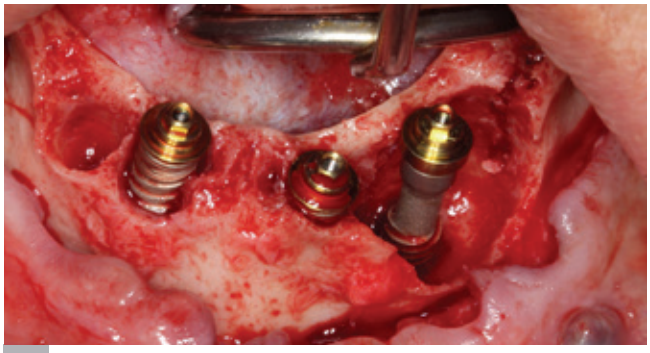

5

The recommended Initial Stability for Immediate Loading (over 45 Ncm) was obtained despite the extensive Bone Loss.

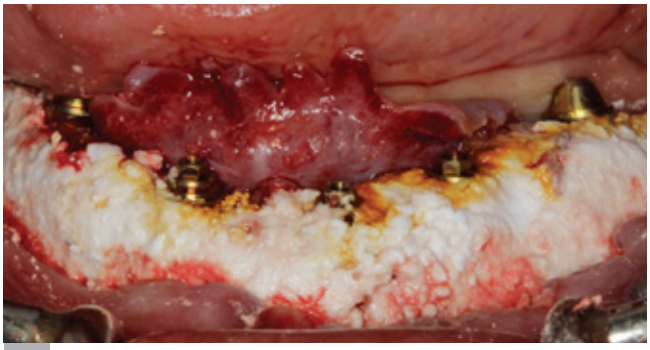

6

Bone Augmentation using HA & Calcium Sulfate Bone Graft.

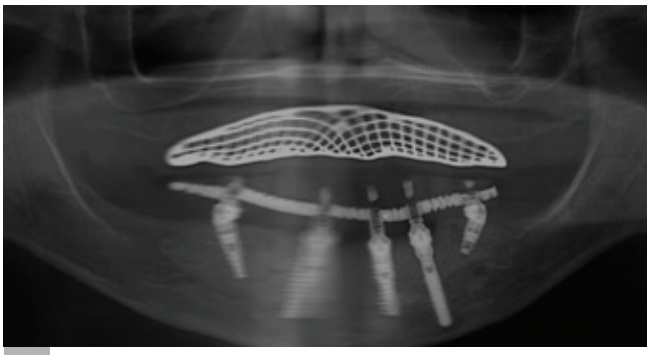

7

Post Op. Panoramic X-Ray, taken at the day of the operation.

8

Six Months Post Op Routine Check-Up shows a healthy Gingiva.

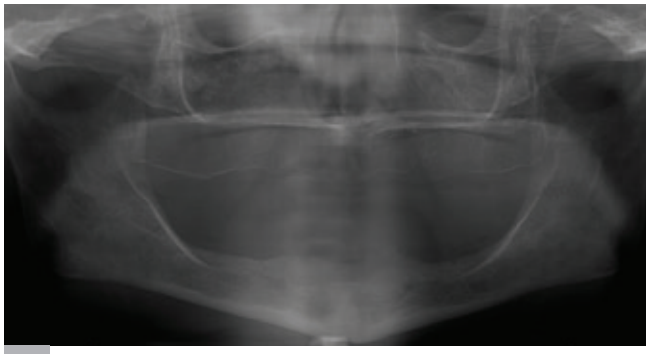

1

Panoramic X-Ray illustrates the severe resorption of Upper and Lower Alveolar Ridge.

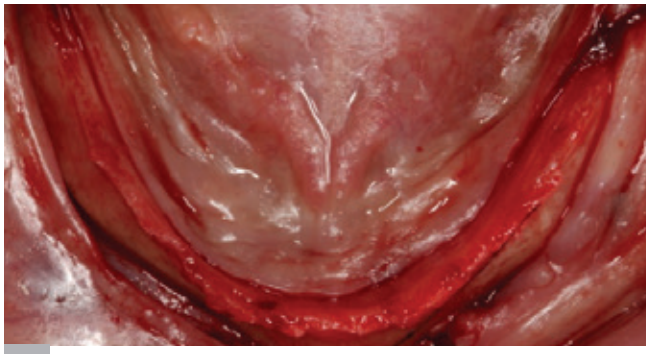

2

3

Elevation of a Mucoperiosteal Flap reveals Knife-Edge Alveolar Ridge (pics. 2-3).

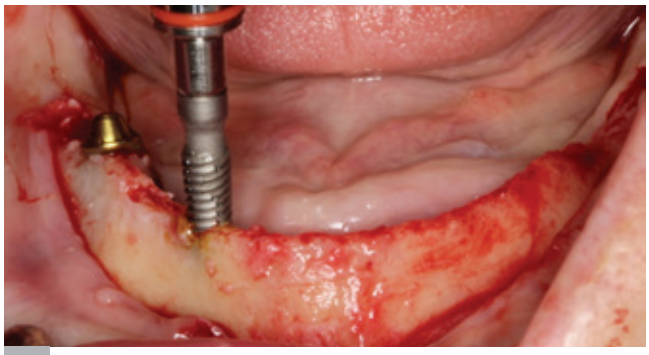

4

Insertion of Cortical Implant.

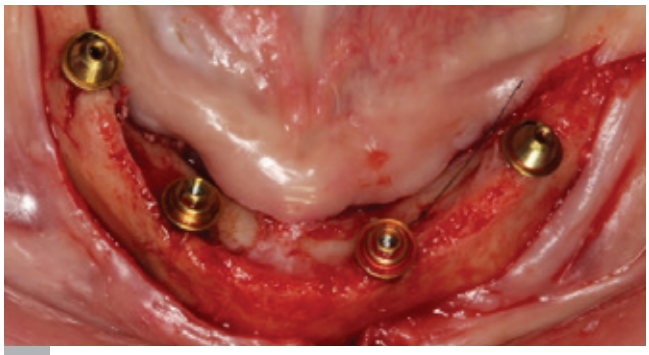

5

Multi- Unit Abutments mounted to the implants.

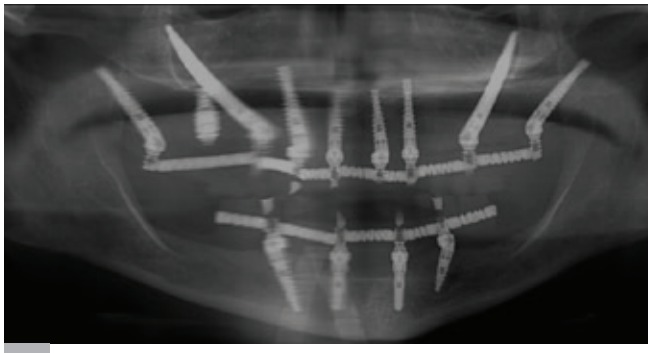

6

Post Op. Panoramic X-Ray taken at the day of the operation.

Socket Shield Technique

The “Socket Shield Technique” has demonstrated the potential in preventing buccal tissue from resorption in animal and clinical studies. It is assumed that retaining a root fragment attached to the buccal bone plate in this technique can avoid tissue alteration after tooth extraction (1).

The Histological outcomes of Socket Shield technique showed that, partial root retention seems not to interfere with osseointegration and may be beneficial in preserving the buccal bone plate (2). It was also found that new bone formation could be observed between the implant and the tooth segments (3).

Socket Shield Advantages (3)

- Aesthetic
- Economic - No grafting and membrane material are needed
- No need for secondary surgery site to gain a connective tissue graft
- Reduced post-operational pain
- Solution for patients with contraindications for major surgery due to their medical history

1. Chen CL, Pan YH. Socket Shield Technique for Ridge Preservation: A Case Report: Journal of Prosthodontics and Implantology 2013;2.
2. Hurzeler MB, Zuhr O, Schupbach P, Rebele SF, Emmanouilidis N, Fickl S. The socket-shield technique: a proof-of-principle report. J Clin Periodontol 2010; 37:855–862.
3. Bäumer, D., Zuhr, O., Rebele, S., Schneider, D., Schupbach, P., & Hürzeler, M. (2013). The Socket-Shield Technique: First Histological, Clinical, and Volumetrical Observations after Separation of the Buccal Tooth Segment - A Pilot Study. Clinical Implant Dentistry and Related Research.

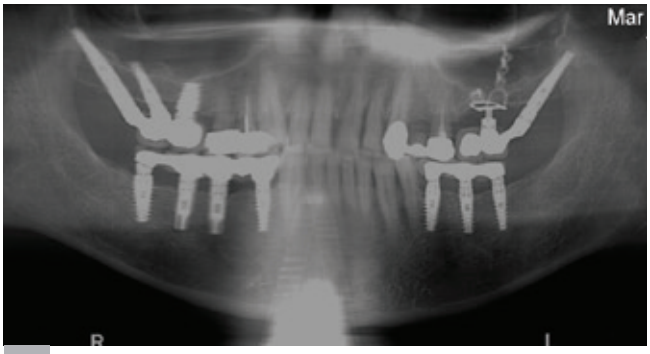

1

Panoramic X-ray illustrates chronic generalized severe periodontitis.

2

CT illustrating the thin buccal plate.

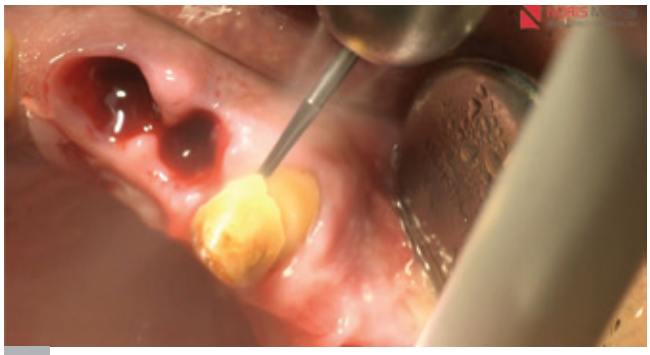

3

Decoronation.

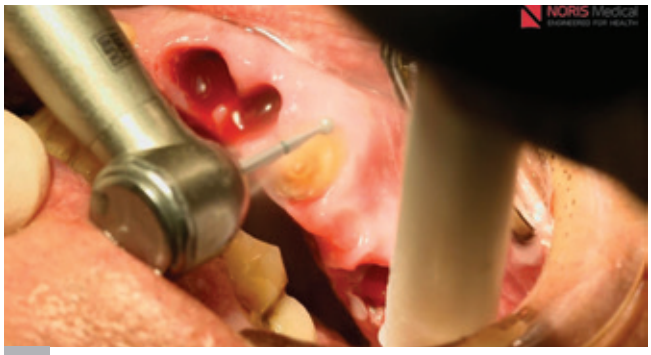

4

Subgingival preparation.

5

Vertical splitting of the root.

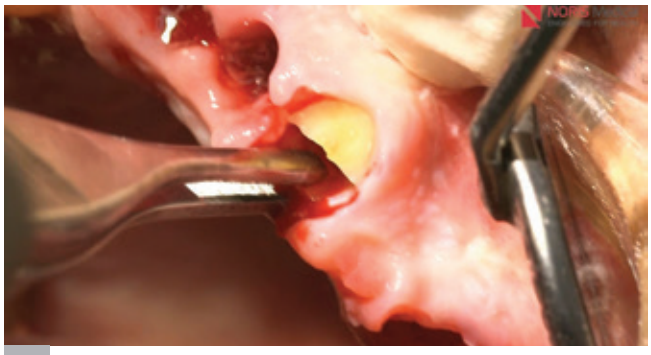

6

Removal of the palatine part of the root.

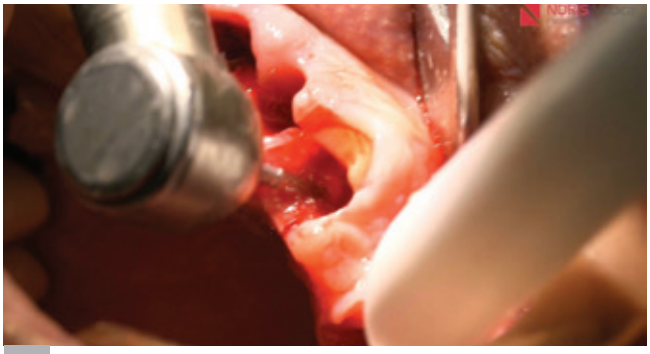

7

Osteotomy preparation.

8

Cortical Implant.

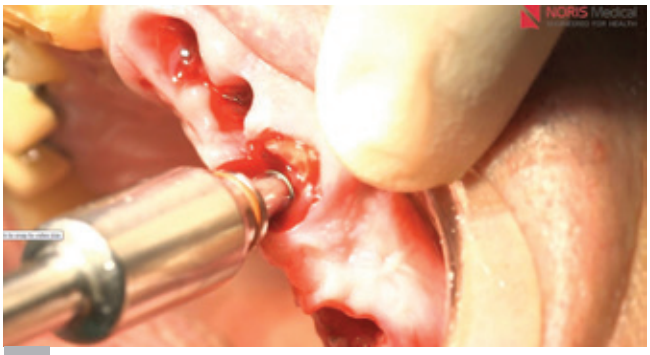

9

Insertion of Cortical implant.

10

Implant in extraction site. The buccal plate is preserved by the root remnants.

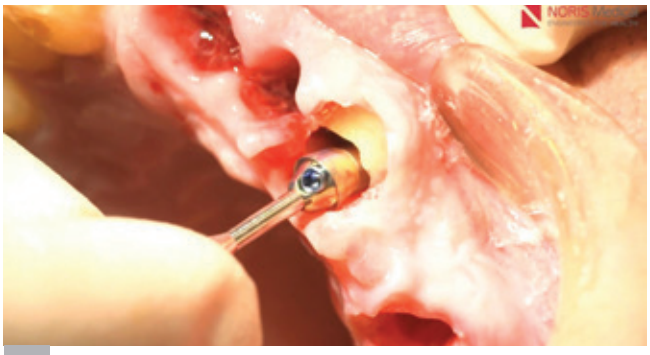

11

Multi-Unit Abutment mounted on the implant.

12

Snap-On Transfer bases are mounted on the Multi-Unit.

13

Impressions using Snap-On transfers.

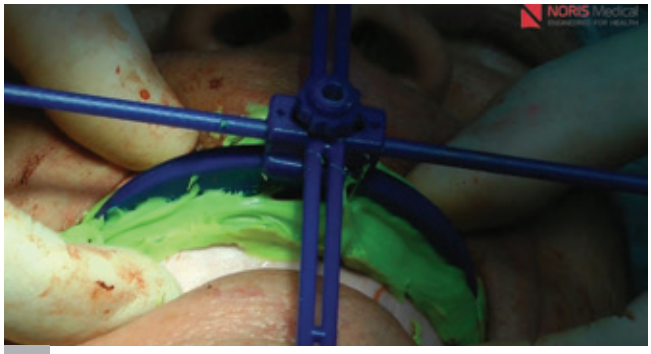

14

Bite Stick – Midline and occlusal plan records, using a bite stick.

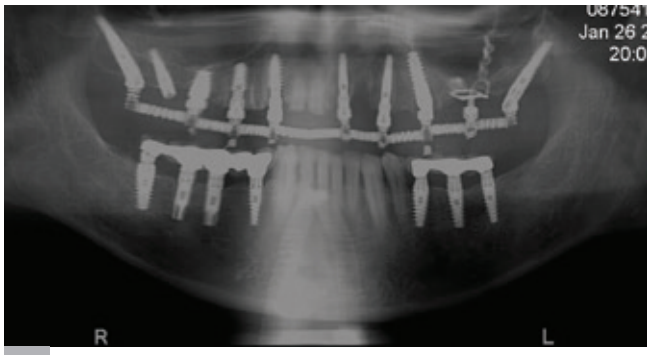

15

Panoramic X-Ray (with the provisional bridge) at the end of the operation.

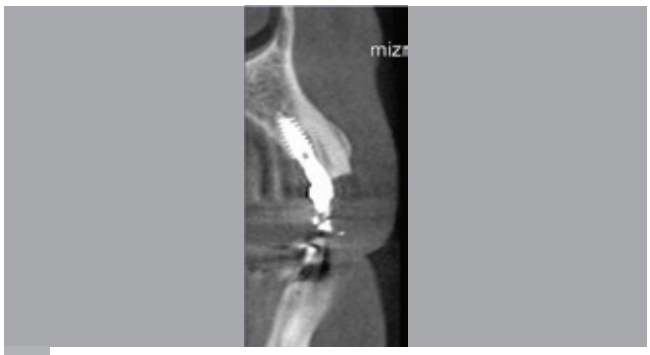

16

CT illustrating the relationship between the implant and the tooth remnants.

17

Pre op.

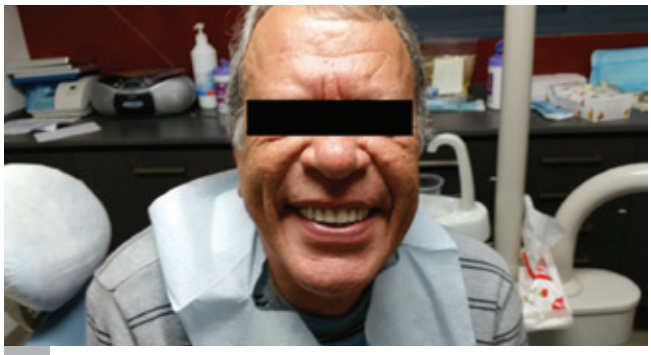

18

Post op.

Notes

LBL011 Rev. 2017-1 EN

www.norismedical.com

NORIS Medical
ENGINEERED FOR HEALTH